

Case report

Variations of the superior thyroid artery and Internal jugular vein

Dr. Mithu Paul¹, Dr. Reshma Ghosh², Dr. Chiranjit Samanta³, Dr. Manotosh Banerjee⁴, Dr. Saktipada Pradhan⁵, Dr. Maitreyee Kar⁶, Dr. Asutosh Pramanik⁷, Prof. (Dr.) Sudeshna Majumdar⁸

¹Junior Resident, Department of Anatomy, Nilratan Sircar Medical College, Kolkata – 700014, West Bengal, India.

²Junior Resident, Department of Anatomy, Nilratan Sircar Medical College, Kolkata – 700014, West Bengal, India.

³Junior Resident, Department of Anatomy, Nilratan Sircar Medical College, Kolkata – 700014, West Bengal, India.

⁴Junior Resident, Department of Anatomy, Nilratan Sircar Medical College, Kolkata – 700014, West Bengal, India.

⁵Junior Resident Department of Anatomy, Nilratan Sircar Medical College, Kolkata – 700014, West Bengal, India.

⁶Associate Professor, Department of Anatomy and the Dean of Student's Affair, North Bengal Medical College, Sushruta nagar, Darjeeling – 734012. West Bengal, India.

⁷Junior Resident Department of Anatomy, North Bengal Medical College, Sushrutanagar, Darjeeling – 734012. West Bengal, India.

⁸Professor and Head of the Department of Anatomy, North Bengal Medical College, Sushrutanagar, Darjeeling – 734012.

Corresponding author: Dr. Sudeshna Majumdar

Abstract :

The superior thyroid artery (STA) is the first branch of the external carotid artery. The Internal jugular vein is a large vein, collects blood from the skull, brain, face and much of the neck. The external jugular vein is formed by the union of the posterior division of the retromandibular vein and the posterior auricular vein and drains into the subclavian vein at the level of the mid-clavicle.

While doing the routine dissection for MBBS students in the Department of Anatomy, NRS Medical College, Kolkata, in April, 2015, few vascular variations were found in the neck of two cadavers. The right sided superior thyroid artery arose from the point of bifurcation of the common carotid artery in one cadaver and in the other one vein, like the external jugular vein (with similarity in origin) ran in the anterior triangle of neck to drain into the internal jugular vein on left side. The knowledge of such variations is important for any invasive or surgical procedure in the neck. region.

Key words : superior thyroid artery, common carotid and external carotid arteries, external and internal jugular veins.

Introduction

The superior thyroid artery (STA) is the first branch of the external carotid artery and arises from the anterior surface of the external carotid just below the level of the greater cornu of the hyoid bone. It descends along the lateral border of thyrohyoid to reach the apex of true lobe of the thyroid gland, lying medially the **external laryngeal nerve**, which is often posteromedial and therefore, at risk when the

artery is being ligated. The artery may arise from the common carotid artery [1].

Branches : The superior thyroid artery supplies the thyroid gland and the adjacent skin. **Glandular Branches** are **anterior** which runs along the medial side of the upper pole and lateral lobe to supply mainly the anterior surface, a branch of it crosses above the isthmus to anastomose with its fellow of the opposite side; **posterior** which descends on the posterior border to supply the medial and lateral

surfaces and anastomoses with the inferior thyroid artery. Sometimes a **lateral branch** supplies the lateral surface. The artery also has the following six branches – **infrahyoid, superior laryngeal, sternocleidomastoid and cricothyroid** [1]. The **infrahyoid branch** supplies the infrahyoid muscles, passing along the lower border of hyoid bone. The **superior laryngeal artery accompanies the internal laryngeal nerve** and deep to the thyrohyoid pierces the thyrohyoid membrane to supply the upper part of larynx. It anastomoses with the fellow of the opposite side and the inferior laryngeal branch of the inferior thyroid artery[1]. **Sternocleidomastoid branch** descends laterally across the carotid sheath and supplies the middle region of the Sternocleidomastoid muscle. **The cricothyroid branch** supplies the cricothyroid muscle and anastomoses with the fellow of the opposite side [1].

Internal jugular vein is a large vein, collects blood from the skull, brain, superficial parts of the face and much of the neck. It begins in the posterior compartment of skull continuous with the sigmoid sinus. The vein descends in the carotid sheath uniting with the subclavian, posterior to the sternal end of the clavicle to form the brachiocephalic vein. It has a superior bulb (below the tympanic plate) and is also dilated near its end as its inferior bulb. It has the following tributaries:

1. inferior petrosal sinus,
2. facial vein,
3. dorsal and deep lingual veins,
4. pharyngeal veins,
5. superior thyroid and middle thyroid veins [2].

The external jugular vein is formed by the union of the posterior division of the retromandibular

vein and the posterior auricular vein near the mandibular angle. It drains the scalp and face and also some deeper parts to pass obliquely superficial to the sternocleidomastoid to drain into the subclavian vein after crossing the deep fascia. The tributaries, in addition to formative tributaries are posterior external jugular vein, the oblique jugular vein and near its end are the transverse cervical, suprascapular vein and the anterior jugular veins. The occipital vein occasionally joins it [2].

Aims and Objectives

The variations in the origin of the superior thyroid artery and the tributaries of the internal jugular vein with other veins in the neck were studied in this case report to enhance our knowledge in gross and clinical Anatomy.

Materials and Methods

During the routine dissection for undergraduate students in the Department of Anatomy, NRS Medical College, Kolkata, in April, 2015, variations were found in the vessels of neck in two male cadavers aged between 60 to 70 years. Dissection was done minutely in the head and neck region of the two cadavers, structures were observed in details and relevant photographs were taken.

Observations

In the first cadaver, the right superior thyroid artery (STA) arose from the common carotid artery from the point of its bifurcation into external and internal carotid arteries. Then STA bifurcated into a common trunk and the superior laryngeal artery that pierced the thyrohyoid membrane; the common trunk descended medially towards the thyroid gland (Figure – 1). On the left side of neck, no arterial variation was found. In the second cadaver, on the left side of neck, a vein, like the external jugular vein (EJV) was formed by the union of the posterior

division of the retromandibular vein and the posterior auricular vein near the mandibular angle; it descended medially deep to the platysma, superficial fascia and investing layer of deep cervical fascia, to join with the internal jugular vein (emerging deep to the submandibular gland) in the anterior triangle of neck. Before this meeting, a vein in the lower part of the anterior triangle (with which the suprascapular

vein joined) and the anterior jugular vein drained into the vein like EJV. The common facial vein, formed by the union of the anterior division of the retromandibular vein and the facial vein, was found to pass superficial to the submandibular vein to drain into the internal jugular vein (Figure –2). On the right side of neck, no such variation was found.

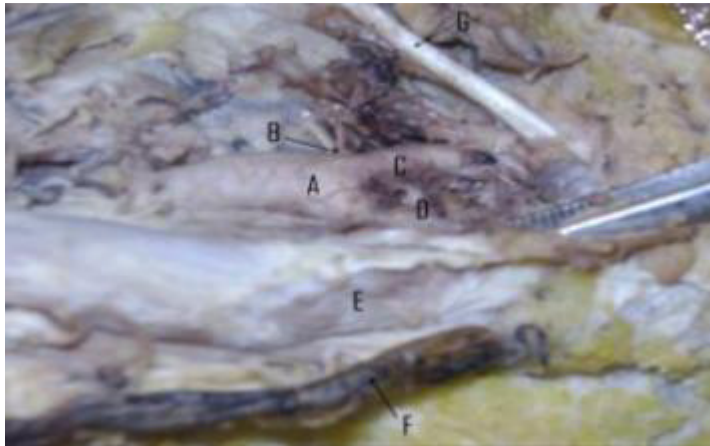


Figure – 1. The right superior thyroid artery (B) arose from the common carotid artery from the point of its bifurcation (A). The external carotid (C) and internal carotid (D) arteries, sternocleidomastoid muscle (E), external jugular vein (F) and the central tendon of digastrics (G) have also been marked here.

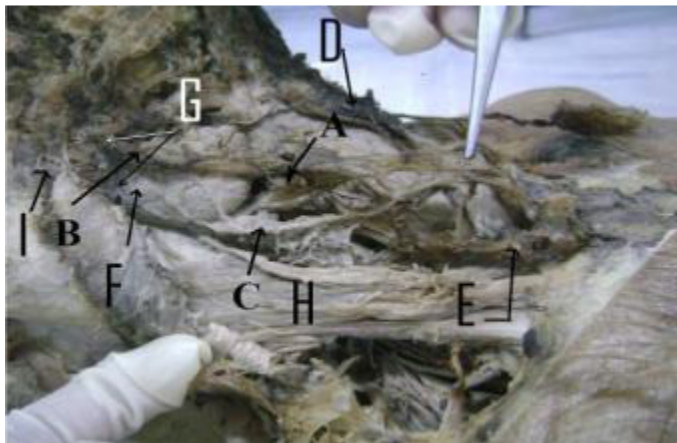


Figure – 2. A vein, like the external jugular vein (C) was formed by the union of the posterior division of the retromandibular vein (G) and the posterior auricular vein (I). It ran in front of the sternocleidomastoid muscle (H) to drain into the internal jugular vein (A). The latter emerged deep to the submandibular salivary gland (F). The anterior jugular vein (D) and a vein in the lower part of the anterior triangle of the neck, with which the suprascapular vein joined (E) drained into ‘C’. The the common facial vein (B) also drained into ‘A’.

Discussion

The Superior thyroid artery (STA) commonly arises from the External carotid artery (ECA) just above the carotid bifurcation. It may also arise from the Common carotid artery (CCA) or from the bifurcation of CCA. Less frequently the STA arises from subclavian artery (SCA) or as a common trunk with the lingual and facial branches of ECA. Rarely the Superior thyroid artery may be absent [3, 4]. According to a study, conducted by Joshi et al, the superior thyroid artery arises from external carotid artery in 66.67% cases, from carotid bifurcation in 31.81% cases and from common carotid artery in 1.51% cases [5]. Pakhiddey et al described a case in 2012, where the left superior thyroid artery originated from common carotid artery (CCA). The point of origin was 1.5 cm proximal to the bifurcation of CCA into external (ECA) and internal carotid arteries (ICA) [6].

A profound knowledge of the anatomic characteristics and variation of the superior thyroid artery such as its origin, course and branching patterns is important for a safe attempt in catheterization, interventional radiology and approach for various surgical procedures in the neck like thyroidectomy, the radical neck dissection, reconstruction surgery for aneurysm, carotid endarterectomy [5, 6]. The knowledge of relationship of superior thyroid artery to external superior laryngeal nerve is very important for surgeons for thyroid surgeries to avoid injuries to the above nerve while ligating STA. During radical neck surgery, the most feared complication is the rupture of the superior thyroid artery and its branches [5]. The Internal jugular vein is a surface projection from the ear lobule to the medial end of the clavicle by a broad band, its inferior bulb is in the depression between

the clavicular head and the sternal head of sternocleidomastoid, in the lesser supraclavicular fossa, where a needle has to be inserted with precision in a living subject [2].

Balachandra et al in 2012, described a case (a male cadaver aged about fifty years), where on the right side the external jugular vein was absent. The retromandibular vein did not divide into anterior and posterior divisions and united with the facial vein to form the common facial vein. The latter united with the posterior auricular vein to drain into the internal jugular vein [7]. Awareness of these variations is important for the surgeons to avoid any intraoperative trial or error procedures which might lead to unnecessary bleeding [8]. Jugular veins are important for any ligations that are performed during radical neck dissection surgeries [7].

External jugular veins are used for catheterization and as venous manometer [7]. The superficial veins, especially the external jugular vein (EJV), are increasingly being utilized for cannulation to conduct diagnostic procedures or intravenous therapies in neck [8]. These veins are usually grafted into the carotid artery during endarterectomy (EJV is used as a recipient for the free flaps) and also used for surgery involving microvascular anastomosis, especially in oral reconstruction procedures [8]. Clinical importance of the internal jugular vein lies in the fact that often inspection, auscultation and Doppler-sonographic examination of the jugular veins may give a clue to the diagnosis of cardiac diseases. Dilatation of these veins indicates possible compression of the superior vena cava by an underlying pathology of the mediastinum or the pericardium [7].

Conclusion

This case report may enhance our knowledge in gross anatomy regarding the blood vessels in the neck

region and will be of help for diagnostic approaches, intravenous therapies, surgical or micro- surgical procedures in the neck.

References

1. Standring S, Mahadevan V, Collins P, Healy JC, Wigley C, Monterio M, Pandeet JJ (editors). In: Gray's Anatomy, The Anatomical Basis of Clinical Practice. Neck. 40th Edition. Spain, Philadelphia; Churchill Livingstone Elsevier.2008; reprinted in 2011; p. 445- 446.
2. Williams PL, Bannister LH, Berry MM, Collins P, Dyson M, Dussek JE, Ferguson MWJ. In: The Anatomical Basis of Medicine and Surgery.Cardiovascular System –veins of the head and neck. ELBS with Churchill Livingstone, London; 1995; p. 1578-1580.
3. Mehta V, Suri RK, Arora J, Rath G, Das S. Anomalous superior thyroid artery. Kathmandu Univ Med J (KUMJ). 2010 Oct-Dec; 8 (32):429-31.
4. Mehta V, Rajesh KS, Jyoti A, Gayatri R, Srijit D. Anomalous (absent) Superior Thyroid Artery. Kathmandu Univ Med J 2010;8(32): 426-8.
5. Joshi A, Gupta S, VaniyaV H. Anatomical variation in the origin of superior thyroid artery and it's relation with external laryngeal nerve. National Journal of Medical Research. Apr – June 2014; Volume 4, Issue 2: 138-141.
6. Pakhiddey R, Samanta PP. Variant origin of left superior thyroid artery from left common carotid: a case report. International Journal of Anatomical Variations. 2013; 6: 143–144.
7. Balachandr N, Padmalatha K, Prakash B, Ramesh BR. Variation of the veins of the head and neck – external jugular vein and facial vein. International Journal of Anatomical Variations. 2012; 5: 99–101.
8. Chauhan NK, Rani A, Chopra J, Anita Rani A, Srivastava AK, Vijay Kumar. Anomalous formation of external jugular vein and its clinical implication. Natl J Maxillofac Surg. 2011 Jan-Jun; 2(1): 51–53.